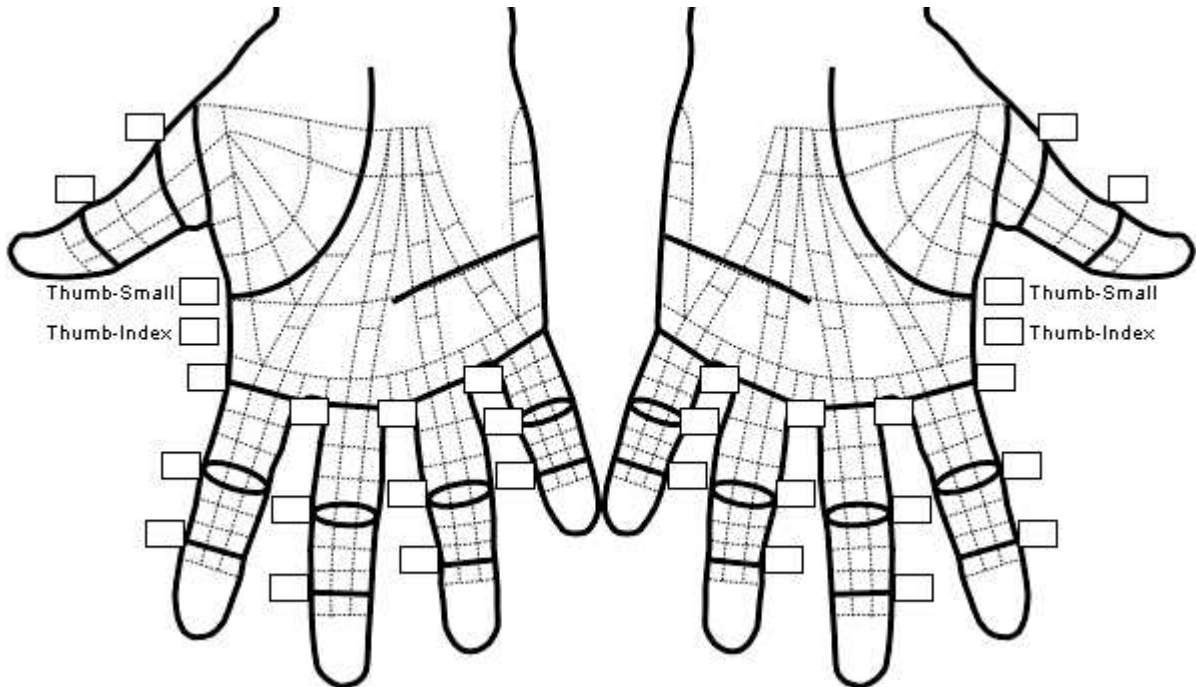


Report of Dupuytren Evaluation

PATIENT: Date:

INITIAL MEASUREMENTS



FINDINGS Joint angles and Spans
Unmeasured: // Cord ⊗ Nodule ◇ Skin Involvement + Scar ⋮ Skin graft ⊕ Doppler Spiral Cord
Measured: Width/Diameter (e.g. 8 mm): ⊠ Cord ⊗ Nodule ◇ Skin Involvement

Right	Left
Palmaris Longus <input type="checkbox"/> Present <input type="checkbox"/> Absent	Palmaris Longus <input type="checkbox"/> Present <input type="checkbox"/> Absent
Doppler <input type="checkbox"/> No exam <input type="checkbox"/> Normal <input type="checkbox"/> Inaudible <input type="checkbox"/> Spiral	Doppler <input type="checkbox"/> No exam <input type="checkbox"/> Normal <input type="checkbox"/> Inaudible <input type="checkbox"/> Spiral
Knuckle Pads: T <input type="checkbox"/> I <input type="checkbox"/> M <input type="checkbox"/> R <input type="checkbox"/> S <input type="checkbox"/>	Knuckle Pads: T <input type="checkbox"/> I <input type="checkbox"/> M <input type="checkbox"/> R <input type="checkbox"/> S <input type="checkbox"/>

Dupuytren's Disease was reviewed in detail with the patient, including discussion of:

- Definition of Dupuytren's Disease
- Risk factors and natural history
- Noninvasive treatment options
- Open surgery - possible complications, short and long term care and expectations
- Percutaneous fasciotomy - possible complications, short and long term care and expectations

Physician, Date